A 72-year-old man is evaluated due to a scaly lesion behind his right ear. A diagnosis of squamous cell carcinoma is confirmed on biopsy, and the patient undergoes excision of the lesion with clear margins. The wound is left to heal by secondary intention. Three weeks later, the patient returns to the office with a 2.5-cm raised, soft, granular lesion at the excision site. Biopsy of a representative lesion is shown in the image below:

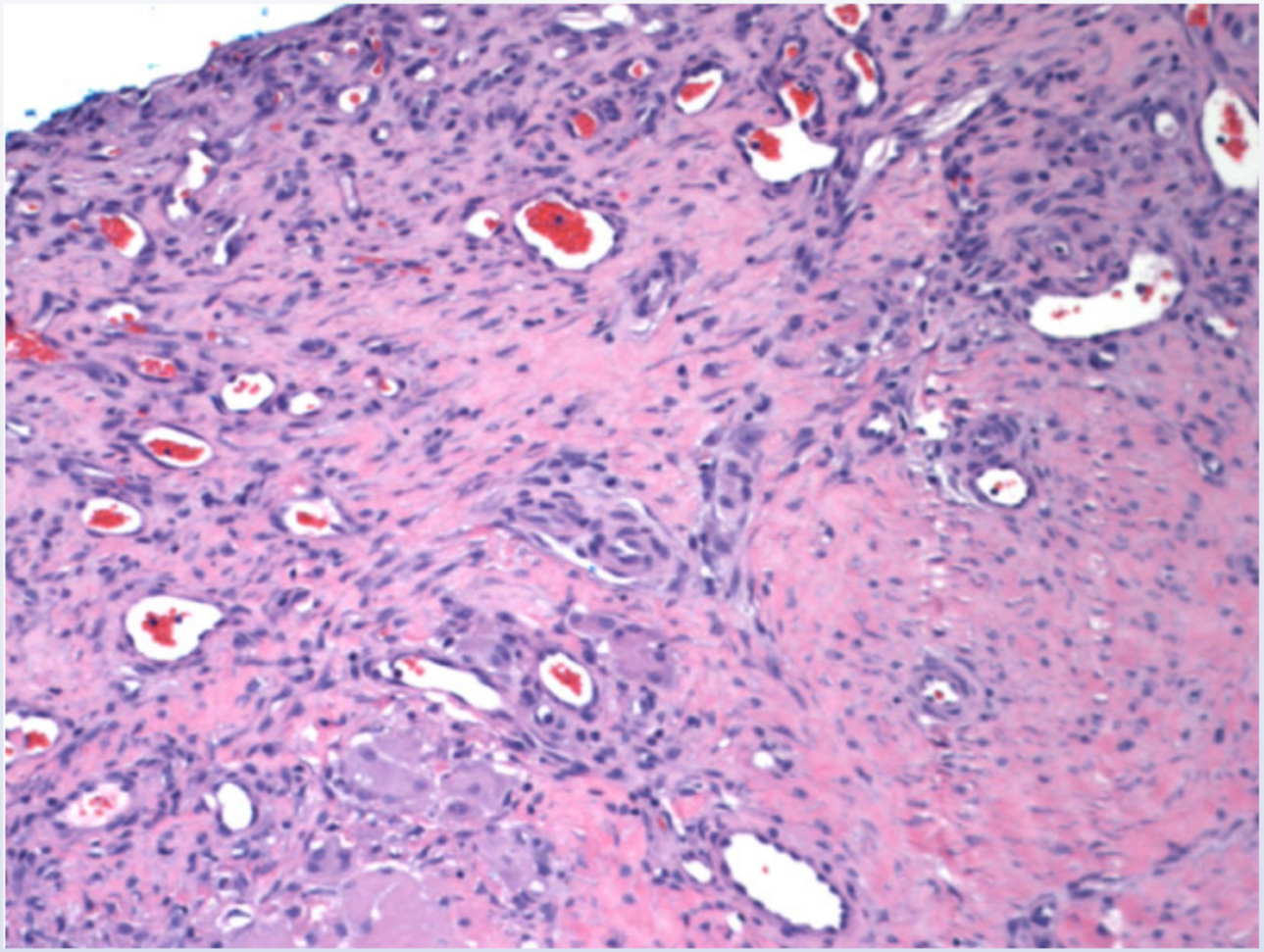

Which of the following is most likely responsible for this patient's postoperative changes?

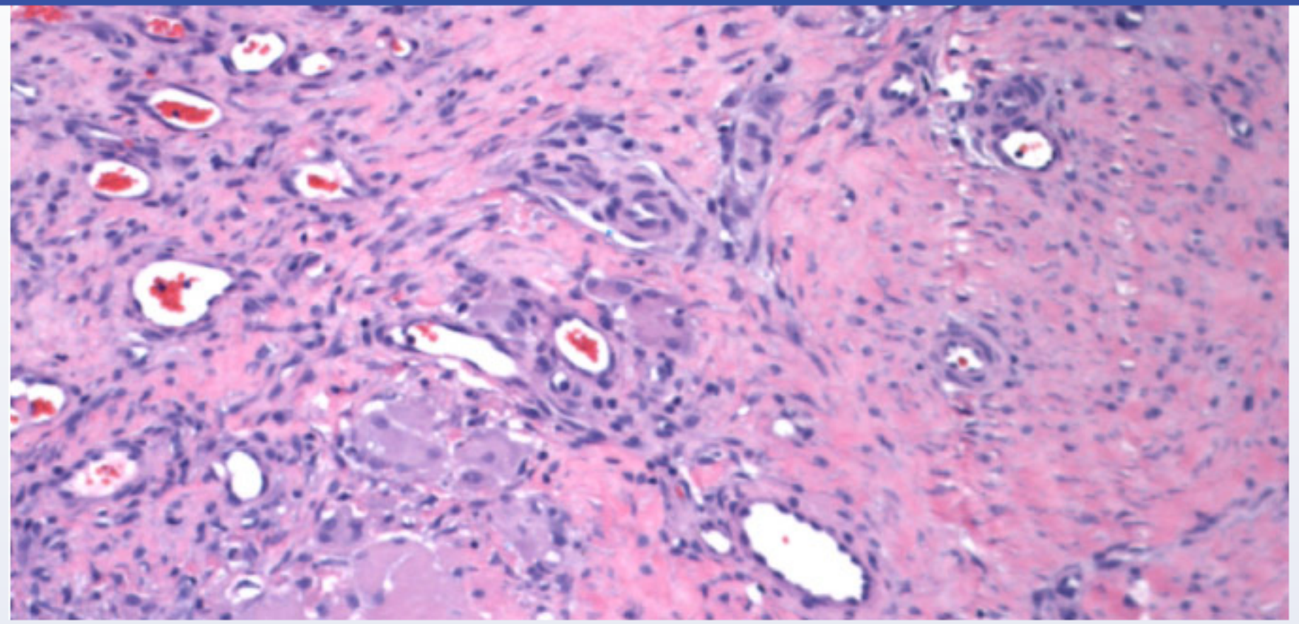

Which of the following is most likely responsible for this patient's postoperative changes?

- A. Deposition of immunoglobulin-derived fibrils
- B. Excess production of type I collagen
- C. Proliferation of dysplastic keratinocytes
- D. Recruitment and degranulation of neutrophils
- E. VEGF-induced tissue proliferation

Submit

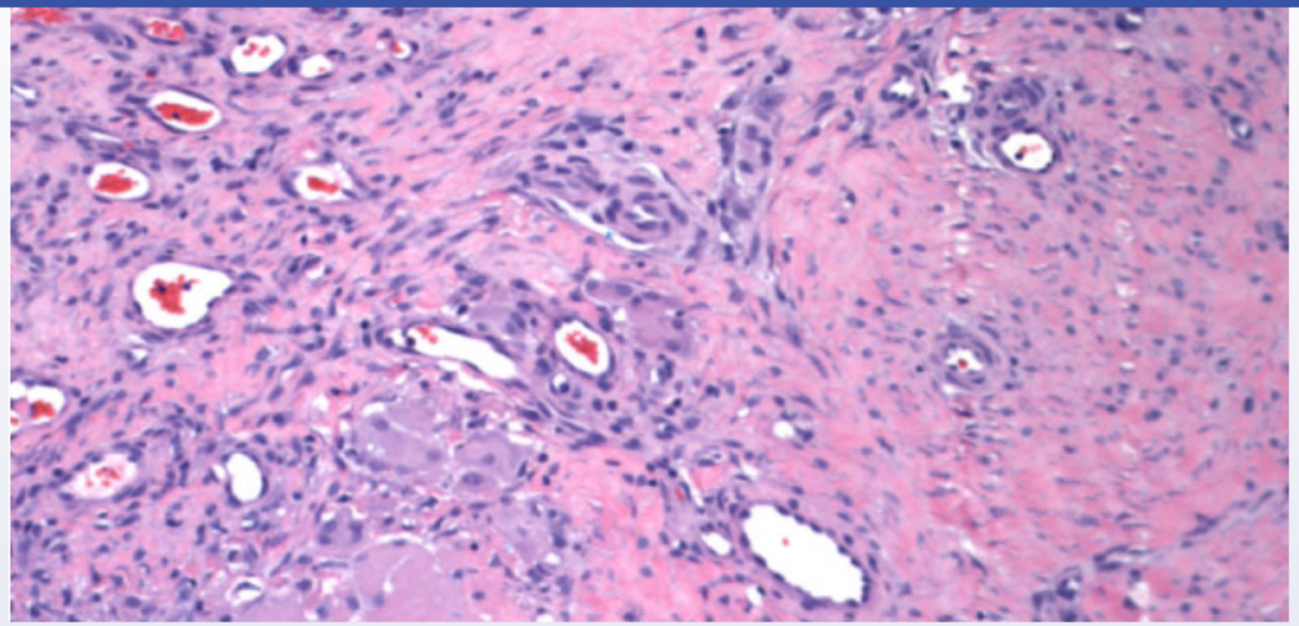

Which of the following is most likely responsible for this patient's postoperative changes?

A. Deposition of immunoglobulin-derived fibrils (1%)

B. Excess production of type I collagen (40%)

C. Proliferation of dysplastic keratinocytes (4%)

D. Recruitment and degranulation of neutrophils (2%)

✓ E. VEGF-induced tissue proliferation (51%)

Omitted
Correct answer

51%
Answered correctly

20 secs
Time Spent

02/27/2020
Last Updated

## Granulation tissue

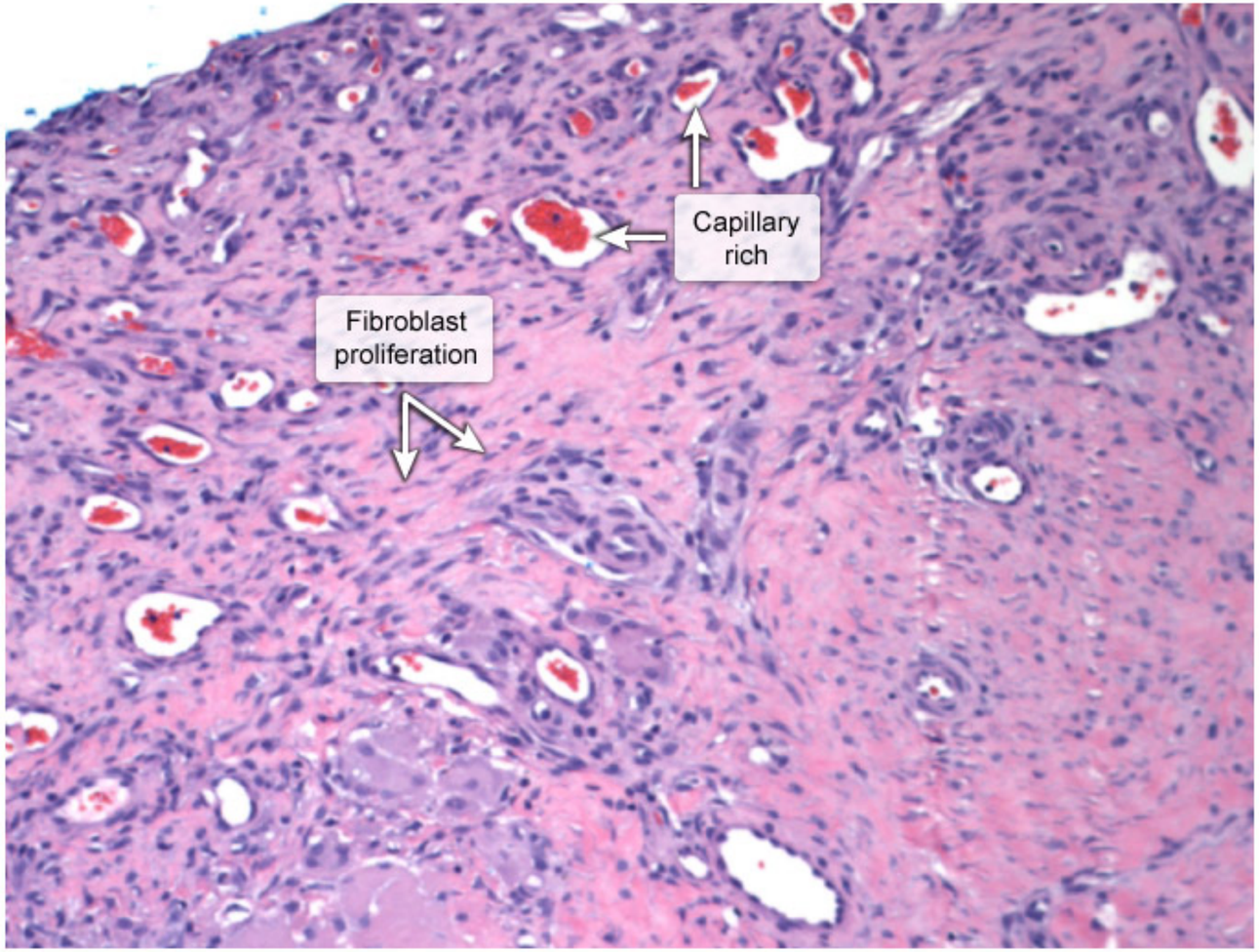


©UWorld

This patient has a lesion with **abundant capillaries and fibroblasts**, which is characteristic of **granulation tissue**. Raising of the lesion above

©UWorld

This patient has a lesion with **abundant capillaries and fibroblasts**, which is characteristic of **granulation tissue**. Raising of the lesion above the surrounding skin (tissue overgrowth) is further consistent with excessive proliferation of granulation tissue (ie, hypergranulation tissue) at the site of wound healing.

Granulation tissue is an essential component of the proliferative phase of normal wound healing, providing the nutrients and structure needed for a wound to fill and reepithelialize. Platelets and macrophages in and around a healing wound produce vascular endothelial growth factor (VEGF), which induces the vascular and fibroblast proliferation of granulation tissue.

However, if **VEGF-induced tissue proliferation** continues unchecked, the resulting hypergranulation tissue prevents wound epithelialization and remodeling. These lesions most often occur at the site of nasogastric tubes or wounds left to **heal by secondary intention** (ie, the wound is purposely left open).

**(Choice A)** Cutaneous amyloidosis is caused by the deposition of insoluble fibers derived from precursor proteins (eg, immunoglobulin light chains) into the superficial dermis. It can have a varied gross appearance (eg, macular, nodular, lichenous) but would be characterized histologically by homogenous, eosinophilic dermal deposits.

**(Choice B)** During the remodeling phase of wound healing, fibroblasts and type III collagen in granulation tissue are gradually (ie, over weeks to years) replaced with myofibroblasts and type I collagen, forming a scar. Abnormalities in this process result in unchecked production of collagen fibers, forming a hypertrophic scar or keloid months after the initial wound.

**(Choice C)** Individuals with a resected squamous cell carcinoma lesion are at risk of developing a secondary lesion at the same site. However, these recurrences typically develop years postresection, and histology would typically show acanthosis, keratinization, and evidence of keratinocyte dysplasia (eg, keratinocytes with pleomorphic nuclei and abundant cytoplasm).

**(Choice D)** Neutrophils are essential to the normal inflammatory response in wound healing; they prevent infection and release cytokines and growth factors that allow wound healing to progress. However, protracted inflammation and excessive release of reactive oxygen species by neutrophils in a wound can cause tissue damage that delays wound healing, resulting in a chronic, nonhealing wound.

**Educational objective:**
Fibroblast and vascular proliferation (ie, granulation tissue) induced by vascular endothelial growth factor (VEGF) is essential to normal wound healing. However, if this tissue proliferation becomes excessive (eg, in wounds left to heal by secondary intention), the resulting hypergranulation

which induces the vascular and fibroblast proliferation of granulation tissue.

However, if **VEGF-induced tissue proliferation** continues unchecked, the resulting hypergranulation tissue prevents wound epithelialization and remodeling. These lesions most often occur at the site of nasogastric tubes or wounds left to **heal by secondary intention** (ie, the wound is purposely left open).

**(Choice A)** Cutaneous amyloidosis is caused by the deposition of insoluble fibers derived from precursor proteins (eg, immunoglobulin light chains) into the superficial dermis. It can have a varied gross appearance (eg, macular, nodular, lichenous) but would be characterized histologically by homogenous, eosinophilic dermal deposits.

**(Choice B)** During the remodeling phase of wound healing, fibroblasts and type III collagen in granulation tissue are gradually (ie, over weeks to years) replaced with myofibroblasts and type I collagen, forming a scar. Abnormalities in this process result in unchecked production of collagen fibers, forming a hypertrophic scar or keloid months after the initial wound.

**(Choice C)** Individuals with a resected squamous cell carcinoma lesion are at risk of developing a secondary lesion at the same site. However, these recurrences typically develop years postresection, and histology would typically show acanthosis, keratinization, and evidence of keratinocyte dysplasia (eg, keratinocytes with pleomorphic nuclei and abundant cytoplasm).

**(Choice D)** Neutrophils are essential to the normal inflammatory response in wound healing; they prevent infection and release cytokines and growth factors that allow wound healing to progress. However, protracted inflammation and excessive release of reactive oxygen species by neutrophils in a wound can cause tissue damage that delays wound healing, resulting in a chronic, nonhealing wound.

**Educational objective:**
Fibroblast and vascular proliferation (ie, granulation tissue) induced by vascular endothelial growth factor (VEGF) is essential to normal wound healing. However, if this tissue proliferation becomes excessive (eg, in wounds left to heal by secondary intention), the resulting hypergranulation tissue can impair wound reepithelization and remodeling.

| Pathophysiology | Dermatology | Wound healing |
|---|---|---|
| Subject | System | Topic |

Copyright © UWorld. All rights reserved.

Exhibit Display

## Granulation tissue, hypertrophic

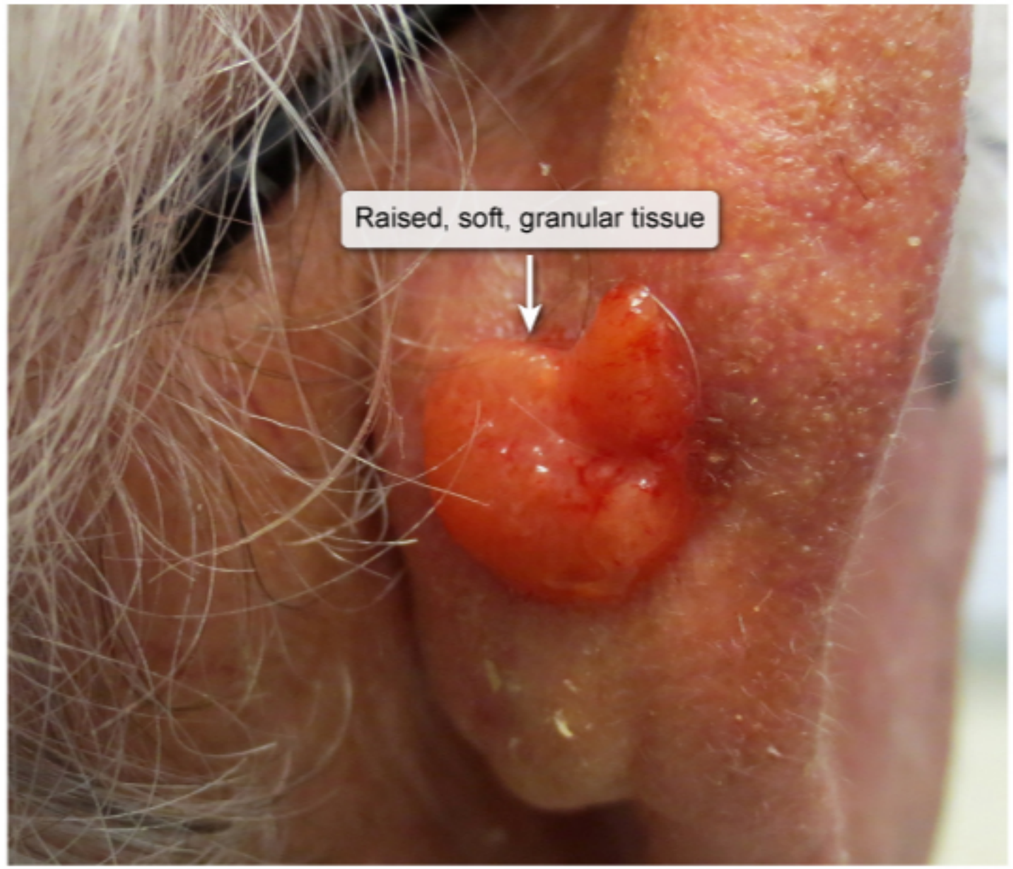


©UWorld

Zoom In
Zoom Out
Reset
Add To Flash Card

(Choice C) Individuals with a resected squamous cell carcinoma lesion are at risk of developing a secondary lesion at the same site. However,

Exhibit Display

## Amyloidosis

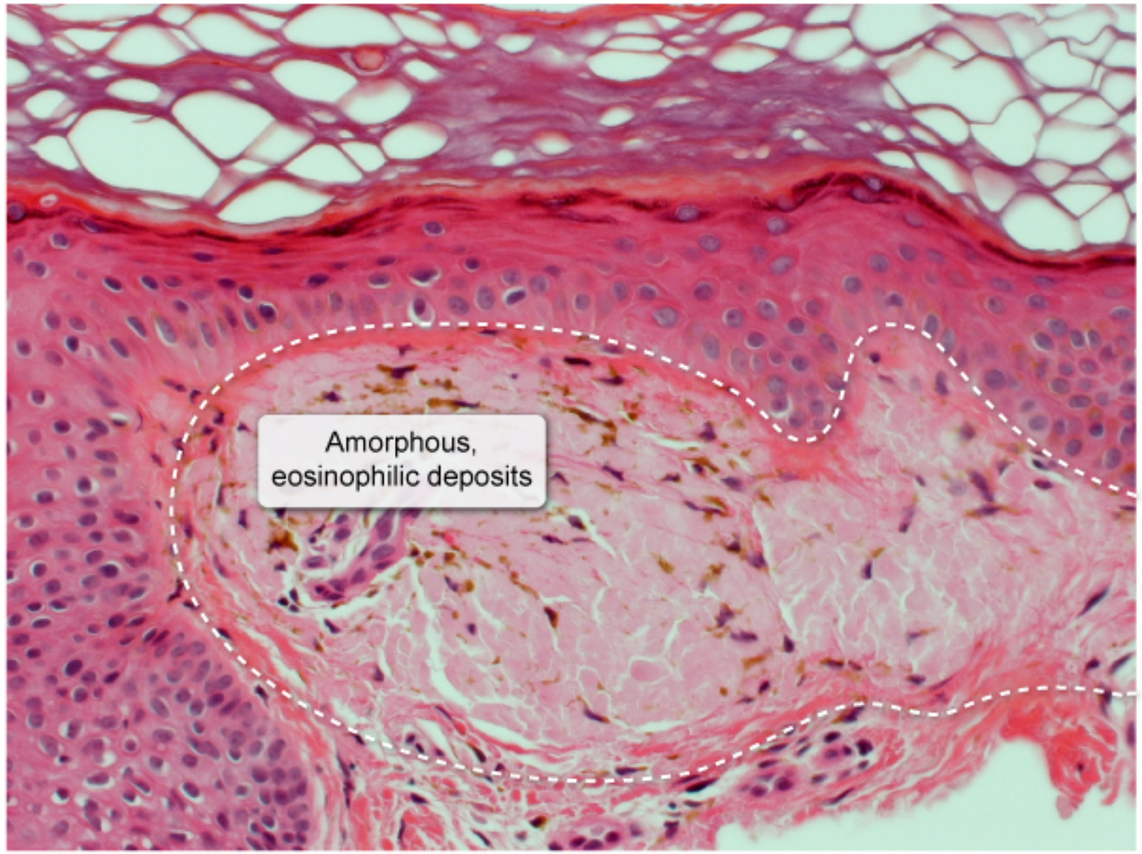


©UWorld

Zoom In Zoom Out Reset Add To Flash Card

(Choice C) Individuals with a resected squamous cell carcinoma lesion are at risk of developing a secondary lesion at the same site. However,

which induces the vascular and fibroblast proliferation of granulation tissue.

**Exhibit Display**

**Keloid**

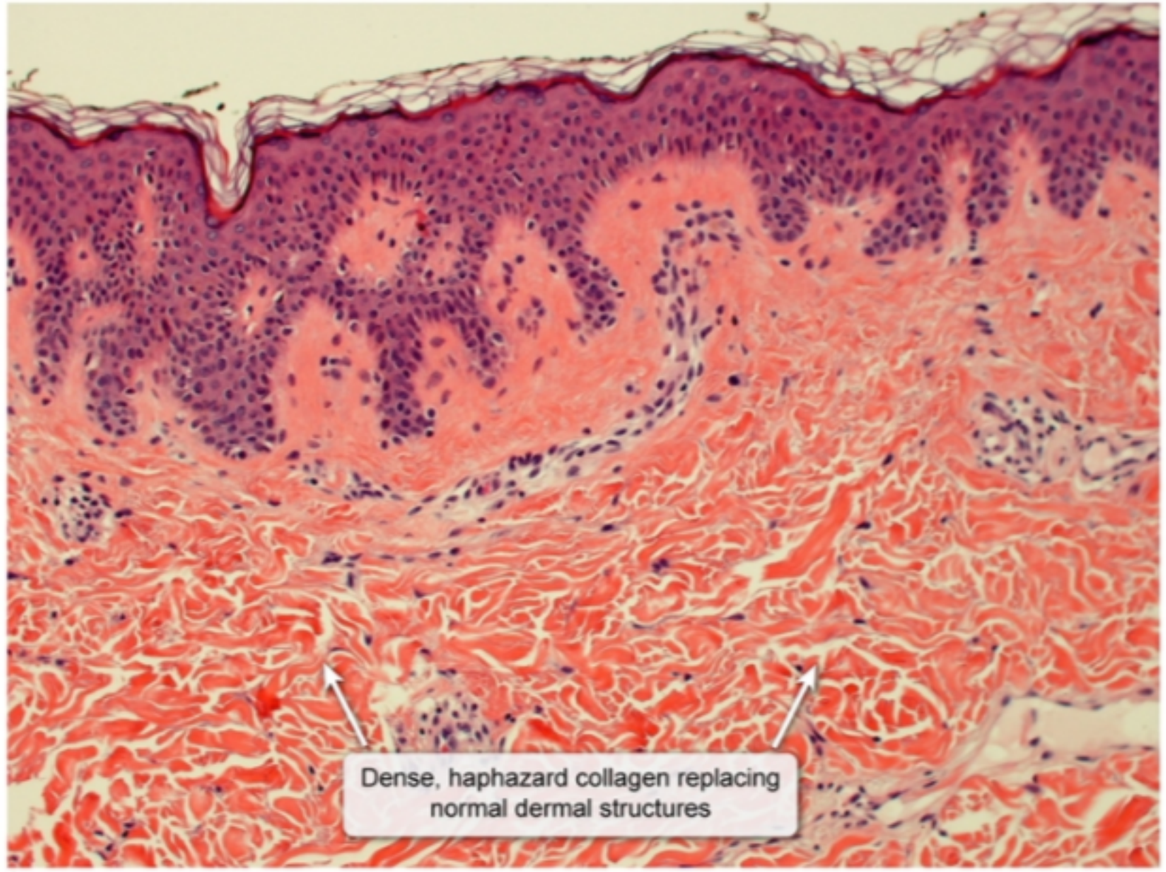


©UWorld

Zoom In Zoom Out Reset Add To Flash Card

Exhibit Display

Zoom In | Zoom Out | Reset | Add To New Card | Existing Card

Which of the following is most likely responsible for this patient's lesion?

- A. Chronic venous insufficiency
- B. Defective type V collagen
- C. Excess collagen formation
- D. Healing by primary intention
- E. Retained foreign body
- F. Wound contraction

Submit

Which of the following is most likely responsible for this patient's lesion?

- A. Chronic venous insufficiency (0%)
- B. Defective type V collagen (1%)
- ✓ C. Excess collagen formation (94%)
- D. Healing by primary intention (1%)
- E. Retained foreign body (0%)
- F. Wound contraction (1%)

Omitted
Correct answer

94%
Answered correctly

10 secs
Time Spent

01/15/2020
Last Updated

**Normal wound healing**

| Phase | Timeline (after injury) | Characteristics |
|---|---|---|
| **Hemostasis** | 0-1 day | • Vasoconstriction, platelet aggregation, fibrin deposition |
| **Inflammatory** | 1-3 days | • Neutrophil migration & macrophage phagocytosis of necrotic debris & bacterial contaminants |
| **Proliferative** | 3 days - 3 weeks | • Formation of granulation tissue:<br>○ Fibroblasts begin to form connective tissue<br>○ Endothelial cells begin to form blood vessels (neovascularization)<br>• Wound contraction |
| **Maturation (remodeling)** | 3 weeks - several months | • Fibroblasts continue to synthesize connective tissue matrix (eg, collagen, elastin)<br>• Slow, progressive increase in tensile strength of new tissue |

©UWorld

**Excessive collagen formation** during the remodeling phase of wound healing can result in a **keloid** or hypertrophic scar. Keloids and hypertrophic scars consist of connective tissue rich in fibroblasts, myofibroblasts, and bundles of collagen fibers that are arranged in a disorganized fashion (black arrow) in keloids and in parallel in hypertrophic scars.

©UWorld

**Excessive collagen formation** during the remodeling phase of wound healing can result in a **keloid** or hypertrophic scar. Keloids and hypertrophic scars consist of connective tissue rich in fibroblasts, myofibroblasts, and bundles of collagen fibers that are arranged in a disorganized fashion (black arrow) in keloids and in parallel in hypertrophic scars.

Normally, wound contraction **(Choice F)**, a normal part of the proliferative phase of wound healing, involves contraction of actin in myofibroblasts to approximate wound edges. Transformation growth factor-beta (TGF-β) promotes differentiation of fibroblasts into myofibroblasts and should diminish on completion of wound repair. In keloids, TGF-β is produced excessively without regulation. As a result, keloids **extend beyond the borders** of the original wound, do not regress, and often recur after resection. They arise following minor (eg, ear piercing) or major (eg, full-thickness burn) trauma and can be **raised, painful**, and **pruritic**. Keloids can have a familial tendency, particularly in persons of Asian or African ethnicity. Unlike keloids, hypertrophic scars are limited to the wound area and may regress spontaneously.

**(Choice A)** Chronic venous insufficiency is characterized by valvular incompetency and venous hypertension which lead to an overactive inflammatory response. The chronic release of inflammatory markers increases vascular permeability, resulting in edema, and proteolytic enzymes cause chronic ulceration.

**(Choice B)** Ehlers-Danlos is a connective tissue disorder that classically involves a genetic mutation of type V collagen. This leads to joint hypermobility and skin hyperelasticity and fragility. Due to defective collagen production, wound healing is impaired (eg, frequent dehiscence, longer remodeling phase).

**(Choice D)** Healing by primary intention describes surgical closure of well-approximated wound edges, which decreases the likelihood of significant scarring. In contrast, wound healing by secondary intention (spontaneous healing) is more likely to lead to scarring and prolonged remodeling as the wound edges are not well approximated.

**(Choice E)** The presence of a foreign body in a wound can delay wound healing and increase the risk of infection. It does not increase the likelihood of keloid development.

**Educational objective:**
Keloids result from excessive collagen formation during the remodeling phase of wound healing. They present as raised, painful, and pruritic nodules that grow beyond the wound borders.

©UWorld

Exhibit Display

## Keloid

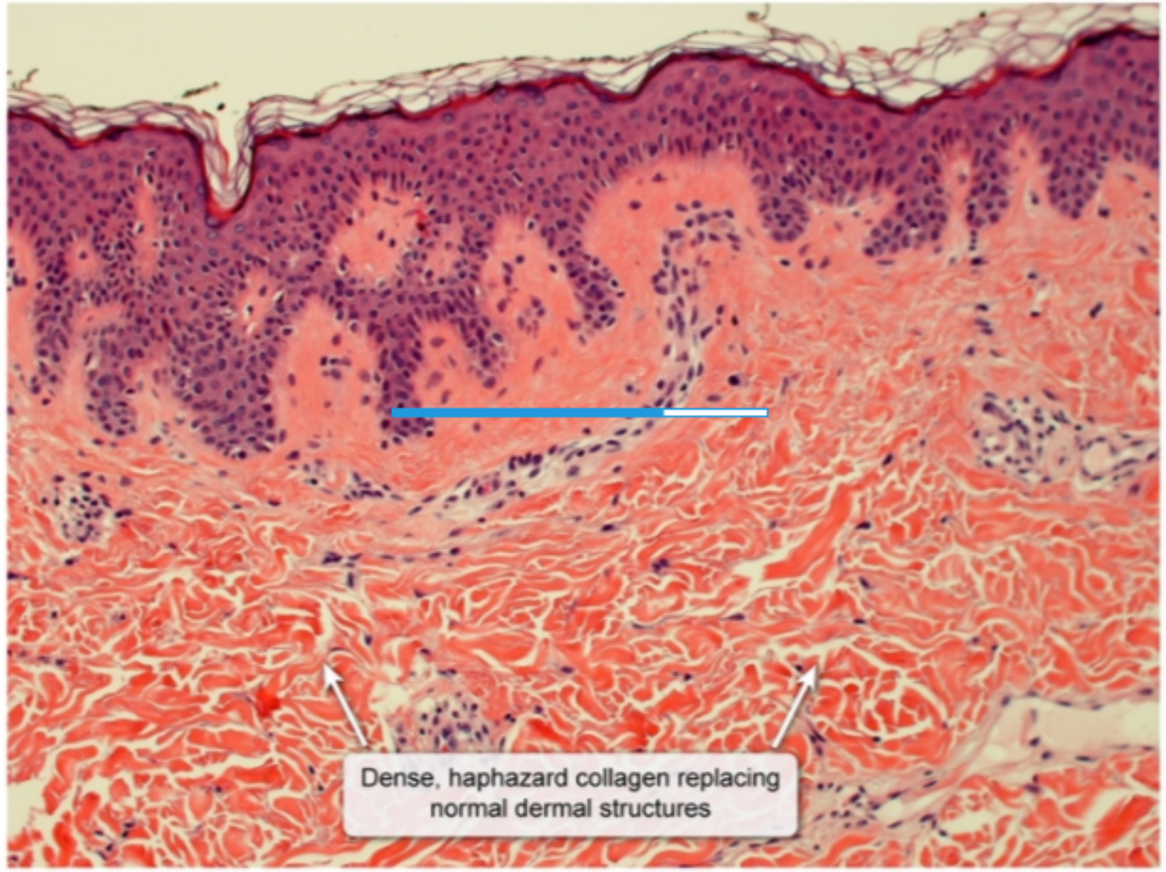


©UWorld

Zoom In | Zoom Out | Reset | Add To New Card | Existing Card

©UWorld

## Exhibit Display

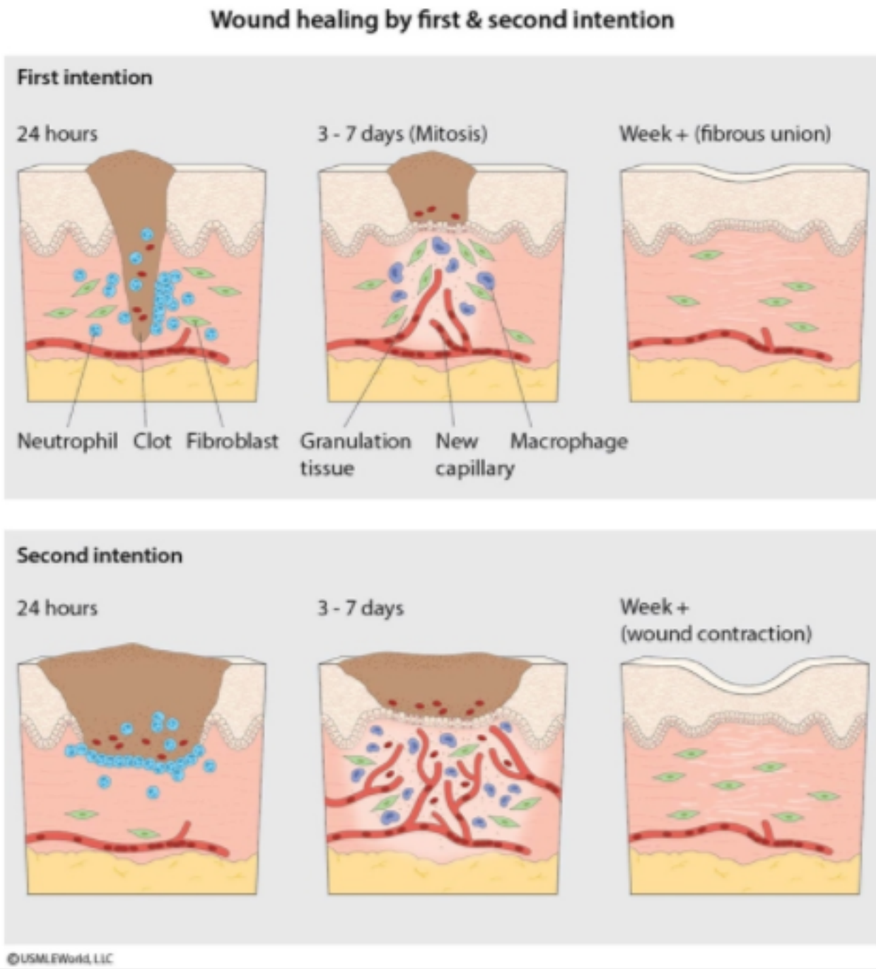


Zoom In | Zoom Out | Reset | Add To New Card | Existing Card

thickness burn) trauma and can be **raised, painful**, and **pruritic**. Keloids can have a familial tendency, particularly in persons of Asian or African ethnicity. Unlike keloids, hypertrophic scars are limited to the wound area and may regress spontaneously.

**(Choice A)** Chronic venous insufficiency is characterized by valvular incompetency and venous hypertension which lead to an overactive inflammatory response. The chronic release of inflammatory markers increases vascular permeability, resulting in edema, and proteolytic enzymes cause chronic ulceration.

**(Choice B)** Ehlers-Danlos is a connective tissue disorder that classically involves a genetic mutation of type V collagen. This leads to joint hypermobility and skin hyperelasticity and fragility. Due to defective collagen production, wound healing is impaired (eg, frequent dehiscence, longer remodeling phase).

**(Choice D)** Healing by primary intention describes surgical closure of well-approximated wound edges, which decreases the likelihood of significant scarring. In contrast, wound healing by secondary intention (spontaneous healing) is more likely to lead to scarring and prolonged remodeling as the wound edges are not well approximated.

**(Choice E)** The presence of a foreign body in a wound can delay wound healing and increase the risk of infection. It does not increase the likelihood of keloid development.

**Educational objective:**
Keloids result from excessive collagen formation during the remodeling phase of wound healing. They present as raised, painful, and pruritic nodules that grow beyond the wound borders.

**References**

- Functional histopathology of keloid disease.
- Nine-month-old patient with bilateral earlobe keloids.

| Pathophysiology | Dermatology | Keloid |
|---|---|---|
| Subject | System | Topic |

Copyright © UWorld. All rights reserved.

A 22-year-old woman comes to the office due to several years of facial blemishes that have failed to respond to over-the-counter treatment. The patient has no other medical conditions. She does not use tobacco, alcohol, or illicit drugs. The patient remains outdoors for prolonged periods during the day for her work. Skin examination findings are shown below.

Which of the following most likely contributed to the pathogenesis of this patient's skin condition?

A. Bacterial degradation of apocrine gland secretions

B. Delayed-type hypersensitivity triggered by foreign antigens

C. Estrogen hormonal effect on the sebaceous glands

D. Keratinocyte damage from ultraviolet radiation exposure

E. Proliferation of lipid-utilizing bacteria within pilosebaceous follicles

Submit

A 22-year-old woman comes to the office due to several years of facial blemishes that have failed to respond to over-the-counter treatment. The patient has no other medical conditions. She does not use tobacco, alcohol, or illicit drugs. The patient remains outdoors for prolonged periods during the day for her work. Skin examination findings are shown below.

Which of the following most likely contributed to the pathogenesis of this patient's skin condition?

Which of the following most likely contributed to the pathogenesis of this patient's skin condition?

- A. Bacterial degradation of apocrine gland secretions
- B. Delayed-type hypersensitivity triggered by foreign antigens
- C. Estrogen hormonal effect on the sebaceous glands
- D. Keratinocyte damage from ultraviolet radiation exposure
- E. Proliferation of lipid-utilizing bacteria within pilosebaceous follicles

Submit

Which of the following most likely contributed to the pathogenesis of this patient's skin condition?

A. Bacterial degradation of apocrine gland secretions (6%)

B. Delayed-type hypersensitivity triggered by foreign antigens (0%)

C. Estrogen hormonal effect on the sebaceous glands (10%)

D. Keratinocyte damage from ultraviolet radiation exposure (5%)

✓ E. Proliferation of lipid-utilizing bacteria within pilosebaceous follicles (77%)

Omitted
Correct answer

77%
Answered correctly

06 secs
Time Spent

04/09/2020
Last Updated

**Acne vulgaris** usually presents with closed (whiteheads) or open (blackheads) comedones, papules, pustules, and/or inflammatory nodules on the forehead, nose, cheeks, or chin. Most cases arise in adolescents and **young adults** due to adrenarche-associated enlargement of sebaceous glands and subsequent rises in sebum production.

Follicles clogged with sebum provide an anaerobic, lipid-rich environment for the proliferation of ***Propionibacterium acnes***, an anaerobic diphtheroid that is part of normal skin flora. Replication of this organism within the confined space of a clogged follicle leads to the activation of the innate, humoral, and cell-mediated immune response, the subsequent release of inflammatory cytokines, and, ultimately, follicular rupture and clinically apparent skin lesions.

**(Choice A)** Bacterial metabolism of apocrine secretions contributes to body odor. Bromhidrosis is a condition characterized by excessive and offensive body odor.

**(Choice B)** Erythema nodosum—characterized by painful, subcutaneous nodules, typically in the lower legs—is a form of panniculitis caused by a delayed hypersensitivity reaction to antigens associated with various conditions (eg, herpes simplex).

**(Choice C)** Androgens promote the development of acne by increasing sebaceous growth and secretion. Androgen levels increase during adolescence in both males and females, corresponding to the increased incidence of acne at this age. Estrogens, however, do not appear to have a significant role in promoting the development of acne.

**(Choice D)** Chronic ultraviolet exposure can lead to keratinocyte damage and increase the risk for actinic keratosis (AK). AK presents with scaly papules or plaques on sun-exposed areas of the forehead, nose, ears, and upper cheeks and typically occurs in elderly patients with years of heavy sun exposure.

**Educational objective:**
Acne typically arises in adolescents and young adults due to adrenarche-associated enlargement in sebaceous glands with subsequent increases in sebum production. Follicles clogged with sebum provide the anaerobic, lipid-rich environment necessary for the proliferation of *Propionibacterium acnes*, the skin commensal responsible for acne lesions.

| Pathophysiology | Dermatology | Acne vulgaris |
|---|---|---|
| Subject | System | Topic |

1
2
3
4
5
6

Item 3 of 6
Question Id: 15379

Mark | Previous | Next | Full Screen | Tutorial | Lab Values | Notes | Calculator | Reverse Color | Text Zoom | Settings

## Exhibit Display

Zoom In | Zoom Out | Reset | Add To New Card | Existing Card

Subject System Topic

Block Time Remaining: 00:00:36
TUTOR

6 | Feedback | Suspend | End Block

Exhibit Display

Zoom In
Zoom Out
Reset
Add To New Card | Existing Card

Subject System Topic

## Exhibit Display

Zoom In | Zoom Out | Reset | Add To New Card | Existing Card

Subject System Topic

the forehead, nose, cheeks, or chin. Most cases arise in adolescents and **young adults** due to adrenarche-associated enlargement of sebaceous

Exhibit Display

Zoom In | Zoom Out | Reset | Add To New Card | Existing Card

the forehead, nose, cheeks, or chin. Most cases arise in adolescents and **young adults** due to adrenarche-associated enlargement of sebaceous

Exhibit Display

Zoom In | Zoom Out | Reset | Add To New Card | Existing Card

A 63-year-old woman comes to the office for a routine preventive examination. She has no significant medical problems and takes no medications. The patient consumes a balanced diet; gets regular exercise; and does not use tobacco, alcohol, or illicit drugs. She is up to date on breast, colon, cervical, and lipid screenings. Her physical examination findings are unremarkable. The patient expresses concern about wrinkles around her eyes that make her "look old." A decrease in which of the following is most likely responsible for this patient's complaint?

A. Collagen cross-linking

B. Collagen fibril production

C. Collagenase synthesis

D. Elastin degradation

E. Proline hydroxylation

Submit

A 63-year-old woman comes to the office for a routine preventive examination. She has no significant medical problems and takes no medications. The patient consumes a balanced diet; gets regular exercise; and does not use tobacco, alcohol, or illicit drugs. She is up to date on breast, colon, cervical, and lipid screenings. Her physical examination findings are unremarkable. The patient expresses concern about wrinkles around her eyes that make her "look old." A decrease in which of the following is most likely responsible for this patient's complaint?

- A. Collagen cross-linking (32%)
- ✓ B. Collagen fibril production (38%)
- C. Collagenase synthesis (6%)
- D. Elastin degradation (16%)
- E. Proline hydroxylation (5%)

Omitted
Correct answer
B

38%
Answered correctly

02 secs
Time Spent

07/08/2020
Last Updated

## Explanation

Multiple environmental factors, especially exposure to ultraviolet (UV) light, contribute to aging of the skin. UVB wavelengths are predominantly absorbed in the upper dermis and contribute to sunburn and increased risk of malignancy. **UVA** wavelengths penetrate deeper into skin and cause **photoaging**. UVA produces reactive oxygen species, which activate multiple inflammatory cell-surface receptors and nuclear transcription factors. This leads to **decreased collagen fibril production**, along with upregulation of matrix metalloproteinases (including collagenases) that subsequently degrade type I and III collagen and elastin **(Choices C and D)**.

Photoaging may be visible by age 30-35. Gradual **thinning of the epidermis** is seen, with reduction in subcutaneous fat, blood vessels, hair

Explanation

Multiple environmental factors, especially exposure to ultraviolet (UV) light, contribute to aging of the skin. UVB wavelengths are predominantly absorbed in the upper dermis and contribute to sunburn and increased risk of malignancy. **UVA** wavelengths penetrate deeper into skin and cause **photoaging**. UVA produces reactive oxygen species, which activate multiple inflammatory cell-surface receptors and nuclear transcription factors. This leads to **decreased collagen fibril production**, along with upregulation of matrix metalloproteinases (including collagenases) that subsequently degrade type I and III collagen and elastin **(Choices C and D)**.

Photoaging may be visible by age 30-35. Gradual **thinning of the epidermis** is seen, with reduction in subcutaneous fat, blood vessels, hair follicles, sweat ducts, and sebaceous glands. Rete ridges at the dermoepidermal junction become flattened. This loss of subcutaneous tissue causes the skin to become atrophic and more vulnerable to damage. In addition, there is increased **crosslinking** of collagen **(Choice A)**, with deposition of collagen breakdown products. The atrophic dermis and increased collagen crosslinking, along with desiccation of the stratum corneum, produce the characteristic wrinkling of photoaged skin.

**(Choice E)** Post-translational hydroxylation of proline residues contributes to the stability of the collagen triple helix. This reaction requires ascorbic acid (vitamin C); deficiency of vitamin C leads to scurvy, which is characterized by impaired production and reduced tensile strength of collagen.

**Educational objective**:
Photoaging is a product of excess exposure to ultraviolet A wavelengths and is characterized by epidermal atrophy with flattening of rete ridges. In addition, there is decreased collagen fibril production and increased degradation of collagen and elastin in the dermis.

**References**

- Looking older: fibroblast collapse and therapeutic implications.

| Pathophysiology | Dermatology | Aging |
|---|---|---|
| Subject | System | Topic |

Copyright © UWorld. All rights reserved.

An 18-year-old man comes to the urgent care clinic due to painful erythema affecting his extremities, trunk, and face. He is vacationing in Florida and spent 5 hours at a Gulf coast beach earlier in the day. The patient did not apply any sunscreen as it was cloudy. The physician explains that cloud cover does not afford a high degree of protection against the sun, especially with prolonged exposure in highly reflective environments like the beach. He is advised to wear protective clothing and apply sunscreen to prevent recurrence. Which of the following is most likely to happen within the patient's skin cells as a result of his exposure?

A. Covalent bond formation between adjacent purine bases

B. End-joining repair of double-stranded DNA breaks

C. Endonuclease nicking of the damaged DNA strand

D. Hypermethylation of residues in the undamaged DNA strand

E. Removal of deaminated bases by glycosylase

Submit

An 18-year-old man comes to the urgent care clinic due to painful erythema affecting his extremities, trunk, and face. He is vacationing in Florida and spent 5 hours at a Gulf coast beach earlier in the day. The patient did not apply any sunscreen as it was cloudy. The physician explains that cloud cover does not afford a high degree of protection against the sun, especially with prolonged exposure in highly reflective environments like the beach. He is advised to wear protective clothing and apply sunscreen to prevent recurrence. Which of the following is most likely to happen within the patient's skin cells as a result of his exposure?

- A. Covalent bond formation between adjacent purine bases (20%)
- B. End-joining repair of double-stranded DNA breaks (13%)
- ✓ C. Endonuclease nicking of the damaged DNA strand (57%)
- D. Hypermethylation of residues in the undamaged DNA strand (3%)
- E. Removal of deaminated bases by glycosylase (5%)

Omitted
Correct answer
C

57%
Answered correctly

01 sec
Time Spent

04/12/2020
Last Updated

Explanation

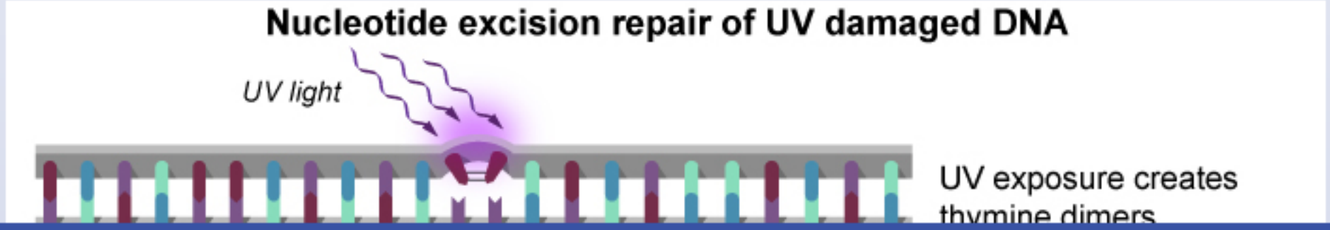

## Nucleotide excision repair of UV damaged DNA

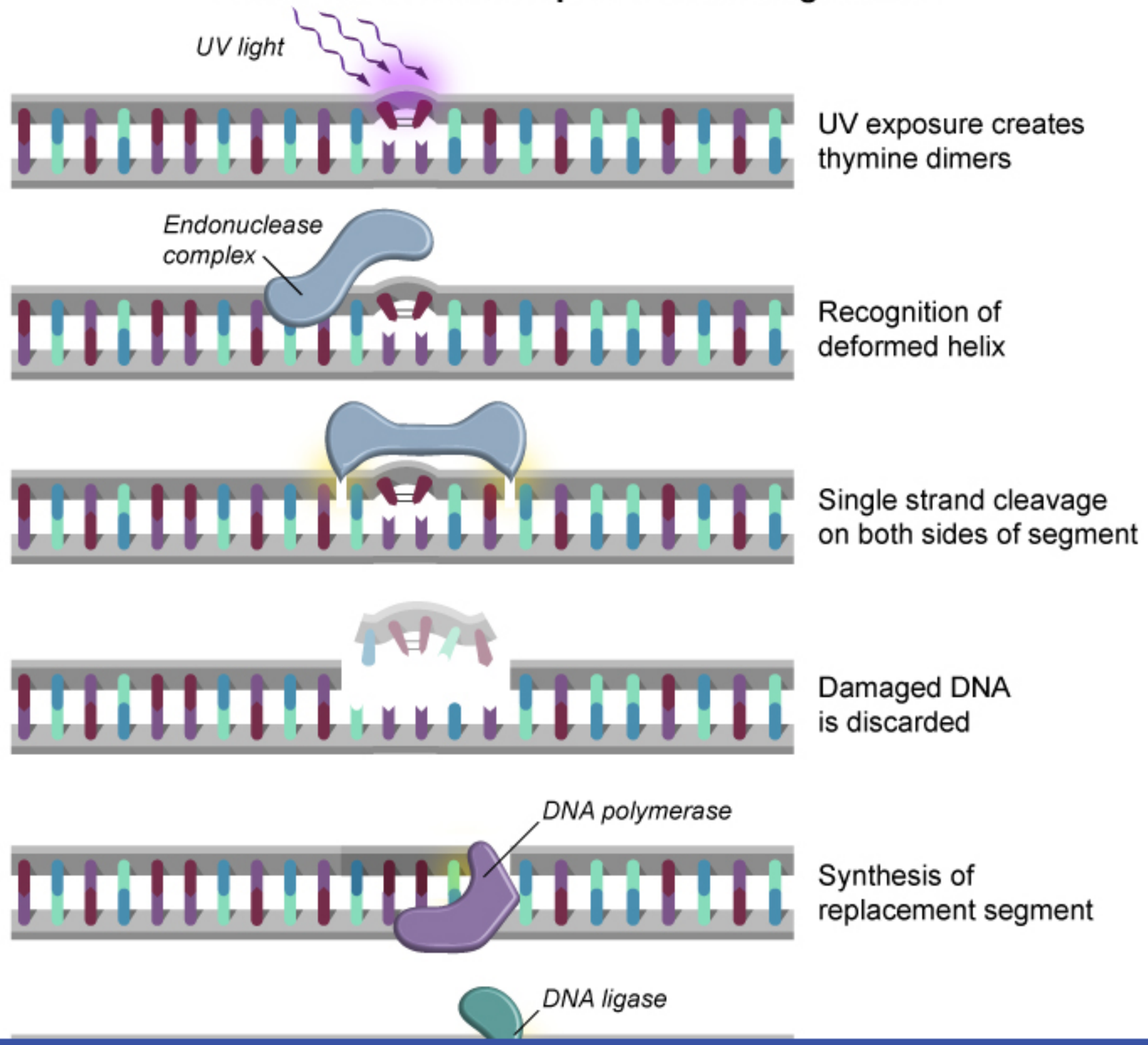

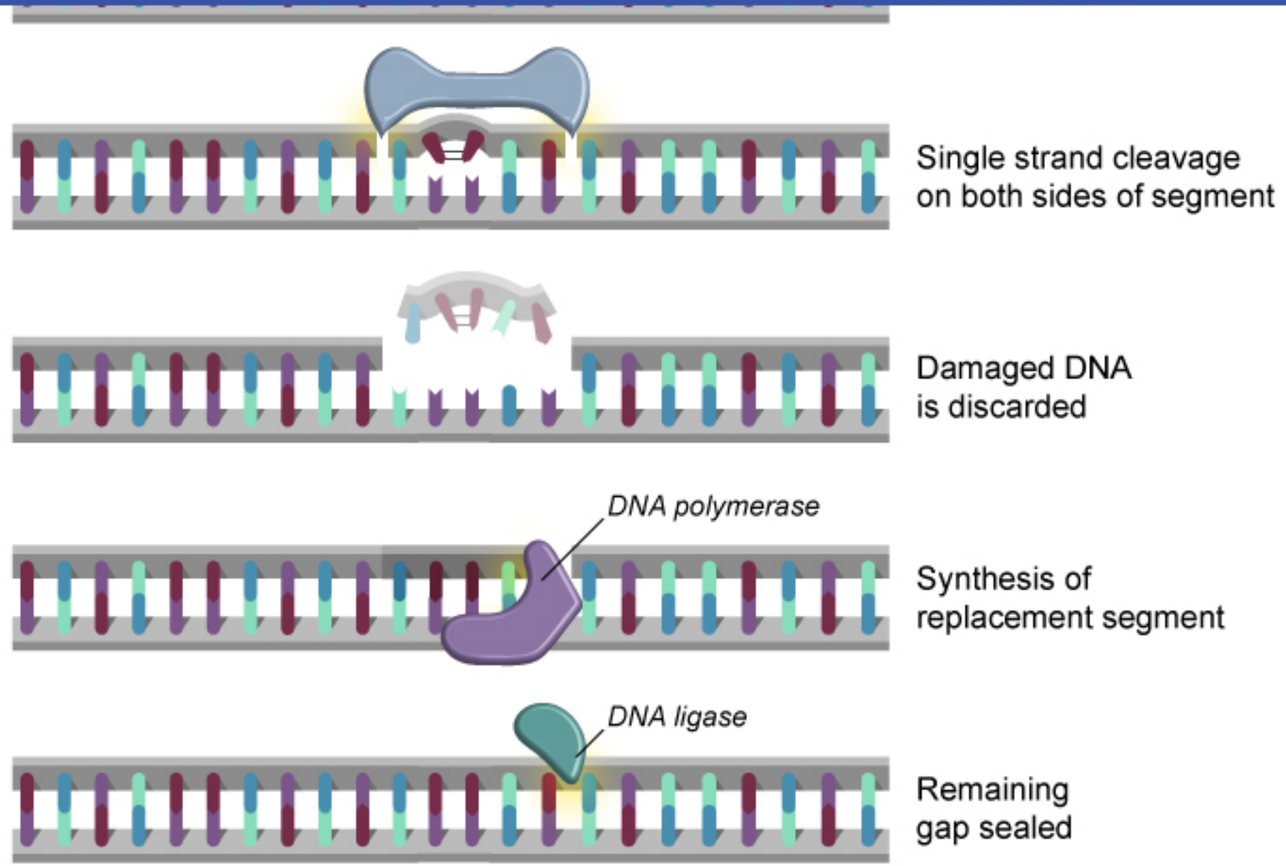


©UWorld

DNA can be damaged by a number of agents, including chemicals, ultraviolet radiation, and ionizing radiation. **Ultraviolet rays** damage DNA primarily through formation of abnormal covalent bonds between adjacent thymine or cytosine residues (**pyrimidine dimers**). The presence of pyrimidine dimers interferes with base recognition during transcription and replication, and **DNA mutations** can result if the damage is not repaired.

Pyrimidine dimers are removed by **nucleotide excision repair**. In this process, a specific endonuclease complex detects abnormalities in the DNA structure caused by the formation of DNA photoproducts. The endonuclease complex then **nicks** the damaged strand on both sides of the pyrimidine dimer, and the defective region is excised. DNA polymerase synthesizes new DNA in the place of the damaged DNA, and DNA ligase

DNA can be damaged by a number of agents, including chemicals, ultraviolet radiation, and ionizing radiation. **Ultraviolet rays** damage DNA primarily through formation of abnormal covalent bonds between adjacent thymine or cytosine residues (**pyrimidine dimers**). The presence of pyrimidine dimers interferes with base recognition during transcription and replication, and **DNA mutations** can result if the damage is not repaired.

Pyrimidine dimers are removed by **nucleotide excision repair**. In this process, a specific endonuclease complex detects abnormalities in the DNA structure caused by the formation of DNA photoproducts. The endonuclease complex then **nicks** the damaged strand on both sides of the pyrimidine dimer, and the defective region is excised. DNA polymerase synthesizes new DNA in the place of the damaged DNA, and DNA ligase seals the final remaining nick.

Mutations that impair the components involved in nucleotide excision repair cause **xeroderma pigmentosum**, a condition characterized by severe photosensitivity and the development of skin cancers at a young age.

**(Choice A)** Ultraviolet radiation causes the formation of pyrimidine-pyrimidine dimers, not purine-purine dimers.

**(Choice B)** Exposure to ionizing radiation (x-rays and gamma rays) causes double-strand DNA breaks. The fractured ends can be joined by nonhomologous end joining.

**(Choice D)** Incorrect base substitution occurs during normal DNA replication and can result in mutations if they are not corrected. DNA mismatch repair in certain prokaryotes is guided by hypermethylation of the parent strand, which helps to identify the non-mutated strand for use as a template.

**(Choice E)** Deamination of DNA bases (eg, cytosine conversion to uracil, adenine to hypoxanthine) can occur spontaneously or secondary to chemical exposure. These errors are corrected by **base excision repair**. In this process, abnormal bases are recognized and removed by specific glycosylases without disruption of the phosphodiester backbone. The apurinic and apyrimidinic residues are then removed by specific endonucleases and replaced with the correct base by DNA polymerase.

**Educational objective:**
Pyrimidine dimers are formed in DNA as a result of ultraviolet light exposure. They are recognized by a specific endonuclease complex that initiates the process of repair by nicking the damaged strand on both sides of the pyrimidine dimer. The damaged segment is then excised, and replacement DNA is synthesized by DNA polymerase.

Pyrimidine dimers are removed by **nucleotide excision repair**. In this process, a specific endonuclease complex detects abnormalities in the DNA structure caused by the formation of DNA photoproducts. The endonuclease complex then **nicks** the damaged strand on both sides of the pyrimidine dimer, and the defective region is excised. DNA polymerase synthesizes new DNA in the place of the damaged DNA, and DNA ligase seals the final remaining nick.

Mutations that impair the components involved in nucleotide excision repair cause **xeroderma pigmentosum**, a condition characterized by severe photosensitivity and the development of skin cancers at a young age.

**(Choice A)** Ultraviolet radiation causes the formation of pyrimidine-pyrimidine dimers, not purine-purine dimers.

**(Choice B)** Exposure to ionizing radiation (x-rays and gamma rays) causes double-strand DNA breaks. The fractured ends can be joined by nonhomologous end joining.

**(Choice D)** Incorrect base substitution occurs during normal DNA replication and can result in mutations if they are not corrected. DNA mismatch repair in certain prokaryotes is guided by hypermethylation of the parent strand, which helps to identify the non-mutated strand for use as a template.

**(Choice E)** Deamination of DNA bases (eg, cytosine conversion to uracil, adenine to hypoxanthine) can occur spontaneously or secondary to chemical exposure. These errors are corrected by **base excision repair**. In this process, abnormal bases are recognized and removed by specific glycosylases without disruption of the phosphodiester backbone. The apurinic and apyrimidinic residues are then removed by specific endonucleases and replaced with the correct base by DNA polymerase.

**Educational objective:**
Pyrimidine dimers are formed in DNA as a result of ultraviolet light exposure. They are recognized by a specific endonuclease complex that initiates the process of repair by nicking the damaged strand on both sides of the pyrimidine dimer. The damaged segment is then excised, and replacement DNA is synthesized by DNA polymerase.

| Pathophysiology | Dermatology | Sunburn |
|---|---|---|
| Subject | System | Topic |

Copyright © UWorld. All rights reserved.

A 14-year-old girl is brought to the office for evaluation of a bump on her chest just below the right breast. The bump has been there for as long as she can remember, but it became a little larger 2-3 years ago. The bump also becomes tender just before she starts her menses. Menarche was at age 12. Her menses occur every 28 days and last 4-5 days. Examination shows Tanner stage 5 breasts. Both breasts and axillae appear normal. There is a soft, raised, hyperpigmented, 0.5-cm nontender lesion inferior to the right breast. Which of the following is the cause of this patient's presentation?

A. Clonal proliferation of benign melanocytes

B. Excessive sunlight exposure

C. Failed involution of the mammary ridge

D. Fat cells in a fibrous capsule

E. Pedunculated outgrowth of normal skin

Submit

A 14-year-old girl is brought to the office for evaluation of a bump on her chest just below the right breast. The bump has been there for as long as she can remember, but it became a little larger 2-3 years ago. The bump also becomes tender just before she starts her menses. Menarche was at age 12. Her menses occur every 28 days and last 4-5 days. Examination shows Tanner stage 5 breasts. Both breasts and axillae appear normal. There is a soft, raised, hyperpigmented, 0.5-cm nontender lesion inferior to the right breast. Which of the following is the cause of this patient's presentation?

- A. Clonal proliferation of benign melanocytes (13%)
- B. Excessive sunlight exposure (0%)
- ✓ C. Failed involution of the mammary ridge (68%)
- D. Fat cells in a fibrous capsule (13%)
- E. Pedunculated outgrowth of normal skin (3%)

Omitted
Correct answer
C

68%
Answered correctly

01 sec
Time Spent

06/27/2020
Last Updated

Explanation

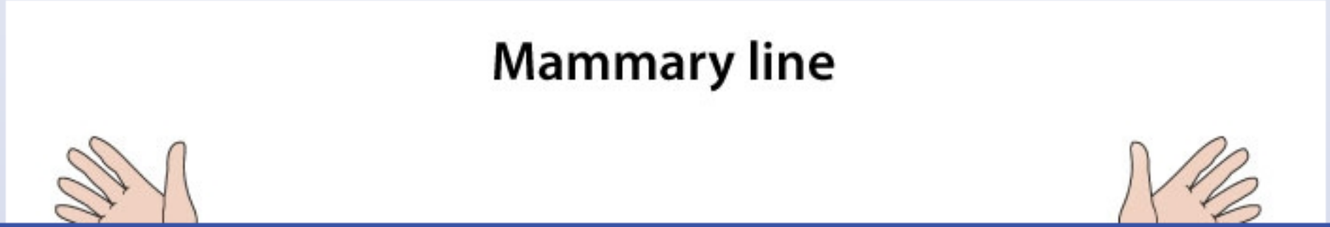

# Mammary line

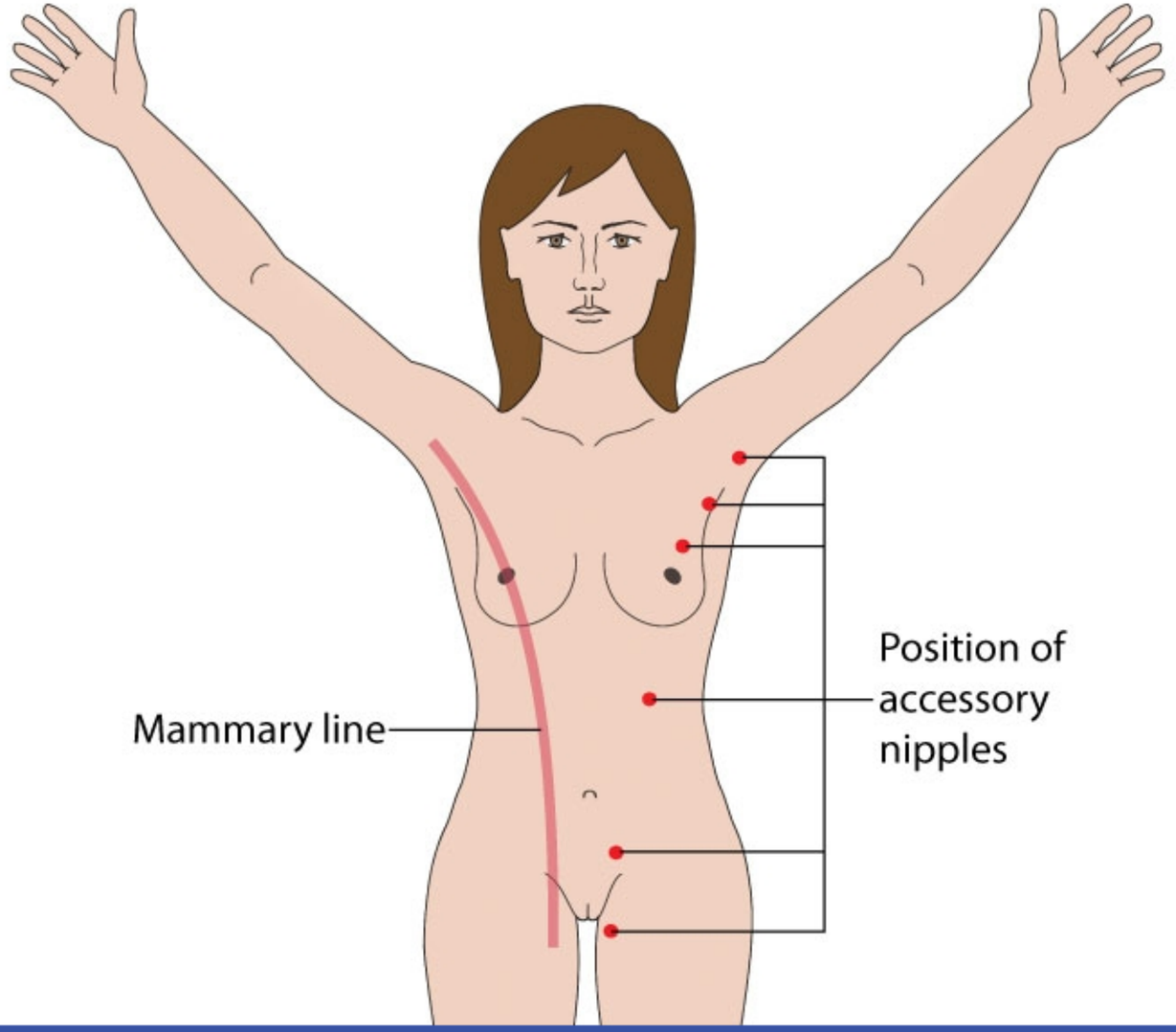

© USMLEWorld, LLC

The most common congenital breast anomalies in women and men are **accessory nipples** (ie, **polythelia, supernumerary nipple**). They are due to **failure of involution of the mammary ridge**. Accessory nipples are usually **asymptomatic**. However, they **may swell or become tender** similar to normal breast tissue before or during menses, pregnancy, and lactation. They can occur anywhere along the embryonic milk line between the axilla and perineum and are bilateral in 50% of patients. Treatment is normally not needed. Histologically, the accessory nipple is identical to a normal nipple. Findings include **hyperpigmentation, epidermal thickening**, pilosebaceous structure of Montgomery areolar tubercles, smooth muscle bundles (areola), and possible mammary glands and multiple ducts.

**(Choice A)** Congenital melanocytic nevi are caused by the clonal proliferation of benign melanocytes in utero. They can be raised and are hyperpigmented.

**(Choice B)** Ephelides (eg, freckles) and solar lentigines are found on sun-exposed areas. Ephelides are caused by increased melanin production by melanocytes, whereas solar lentigo represents an increased proliferation of melanocytes themselves. They are both hyperpigmented and flat, but solar lentigines are often larger and occur in adults.

**(Choice D)** Lipomas are benign fatty tumors contained within a fibrous capsule. They present as a flesh-colored, soft, and painless subcutaneous mass.

**(Choice E)** Acrochorda, or skin tags, are benign and often pedunculated outgrowths of normal skin. They often develop in locations that experience frequent friction, such as beneath breast tissue or the axillae.

**Educational objective:**
Accessory nipples are the most common congenital breast anomaly resulting from failed regression of the mammary ridge in utero. They are usually asymptomatic but can become tender along with breast tissue during times of hormonal fluctuation.

**References**

- Supernumerary nipples: an overview.

| Pathophysiology | Dermatology | Accessory nipple |
|---|---|---|
| Subject | System | Topic |

© USMLEWorld, LLC

Exhibit Display

Zoom In | Zoom Out | Reset | Add To New Card | Existing Card

© USMLEWorld, LLC

Exhibit Display

Zoom In | Zoom Out | Reset | Add To New Card | Existing Card

© USMLEWorld, LLC

Exhibit Display

Zoom In | Zoom Out | Reset | Add To New Card | Existing Card

© USMLEWorld, LLC

Exhibit Display

Zoom In | Zoom Out | Reset | Add To New Card | Existing Card